



# Aesthetic Otoplasty, Reduction of Shell, Neo-antihelix-plasty, Ear Shell Mastoid Reangulation Procedures

**Paoliello V,\* Carlo Paoliello G**

Rua Alberto De Oliveira Santos, Brazil

## Abstract

This study aims to demonstrate the technical approach for the correction of antihelix flattening (Kaye's Method), for shell reduction by wedge resection and for skull reangulation.(Frank Welsh).

**Keywords:** Otoplasty, Resection of the shell, Neo antihelixplasty.

## Purpose

The surgical correction of protruding ears is intended to correct the partial deletion or total agenesis of the anti helix, the widening of the shell when it's present to an abnormal degree, and skull ear angle that is increased in between 45 and 60 degrees (less is desirable).

## Operative Approach

First, we delineate, in the mastoid ear notch a zone to be resected in the desired shape, from the upper pole to near the lobe (Figure 2). Resection of the shell can go from the antihelix to the entry of the external ear canal, including it all, until there is total or partial loss of cartilage surface tension, which can be checked simply by applying pressure with the finger in the ear (in the middle anterior face of the ear). We delineate the new anti-helix to the desired width and length (Figure 6). A tunnel under the perichondrium is made through the back of the ear on the tail of the antihelix. The tunneling can be done with Freer periosteum rhinoplasty detach or appropriate rasps (Figure A). Multiple vertical incisions should be made in this cartilage with a nasal septum scalpel or common scalpel. Bear in mind that only the cartilage is to be incised, preserving the perichondrium. The appropriate amount of antihelix roll is then maintained in the ear that undergone abrasion, shaving or stripping of the cartilage in order to soften it, by reducing the surface tension, to allow it to fold over itself. This is done by

several regular sutures that enter through point shaped incisions along the crest of the shell on the front of the ear. (Figure B and C). These stitches should be made with colorless monofilament nylon 4.0 or 5.0. This approach for the formation of neo antihelix may be done separately or combined with the reduction of the shell, if needed. Some authors prefer abrasion straightforward, in order to obtain the desired results. correction and shell floor ear reangulation Fusiform resection of skin and subcutaneous tissue in an area previously marked retro auricular (Figure 2). Resection of the perichondrium and cartilage, by incising transfixing demarcation with straight needles and methylene blue points in the cartilage of the shell, can be made as a guide for the incision (Figure 3) make a fusiform incision on a line joining these points, drying the cartilage completely. Adjustment of the edges of the remaining areas, can be done with scissors. Anchoring the free top edge of the Shell to the mastoid aponeurosis with as many stitches as needed (Three or four) with monofilament nylon 3.0. Finally suture on skin in the retro auricular groove with running monofilament nylon 5.0 or simply intradermal monocryl 4.0 running suture (Figure 4). Repeat this technique until we have the ideal positioning of the ear at the desired angle thus avoiding the "telephone" deformity.

## Results and Conclusions

With this method, we can get an ideal position of the ear next to the head. The final look is natural, with the final suture positioned

Quick Response Code:



**\*Corresponding author:** Victor Paoliello, Rua Caramuru 104, Vitória ES 29015020, Brazil

**Received:** 15 May, 2021

**Published:** 16 June, 2021

**Citation:** Paoliello V, Carlo PG. Aesthetic Otoplasty, Reduction of Shell, Neo-antihelixplasty, Ear Shell Mastoid Reangulation Procedures. *Mod Res Plast Recon Sur.* 2021;1(2):1–8. 000508

in the retro auricular groove. A remaining vertical wrinkle on the anterior surface of the shell may be present, but, with time, it reduces and becomes acceptable. We have no recurrence of the cases we operated on. The objective of neo antihelix is to promote flattening correction of the antihelix and protruding ear at the top. The use of headbands is recommended for a period of 30 days at home and especially while sleeping.

Diffenbach (1845)- Promoted only skin excision.

Ely (1881) - Excision of the skin and of the shell.

Luckett (1910) - Created a fold of antihelix by excision of a cartilage layer

Mustarde(1963) - Suggested isolated sutures in antihelix

Furnas (1968) - Emphasized the removal of soft tissue and suture shell-mastoid

Frank Welsh (1979) Standardized and simplified the treatment of shell megalia by wide resection. Easier to match asymmetries and better placement in the retroauricularis sulcus with no recurrence of protruding ears.<sup>1-5</sup>

## Acknowledgments

None.

## Funding

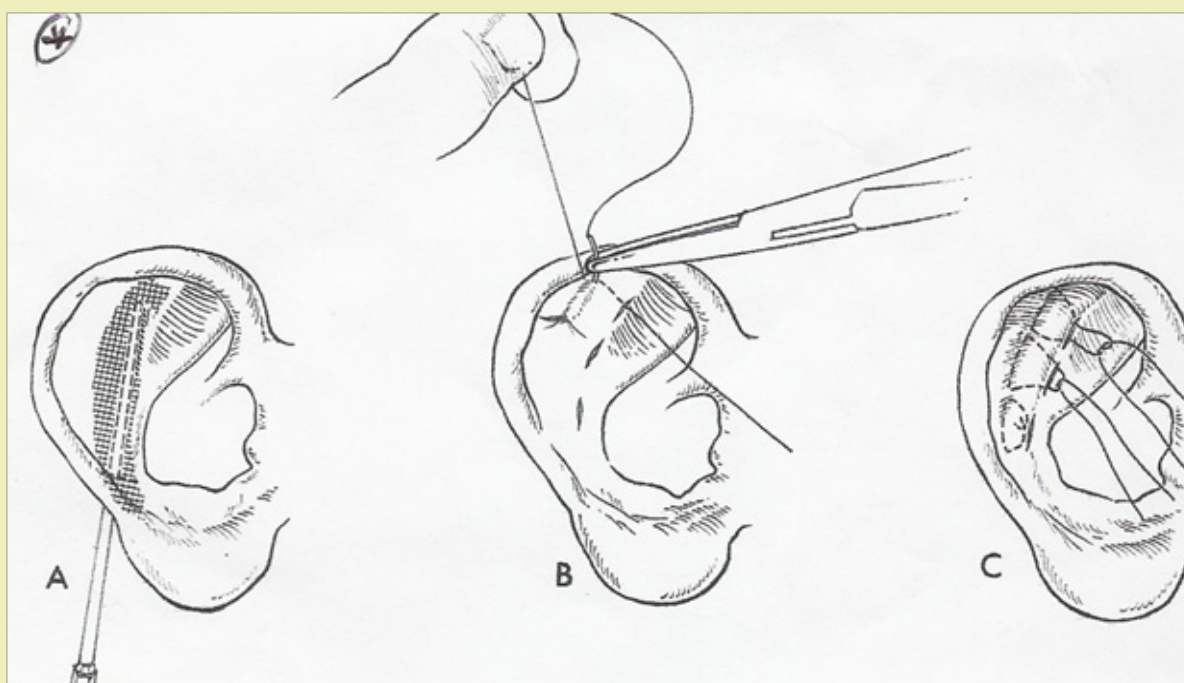
None.

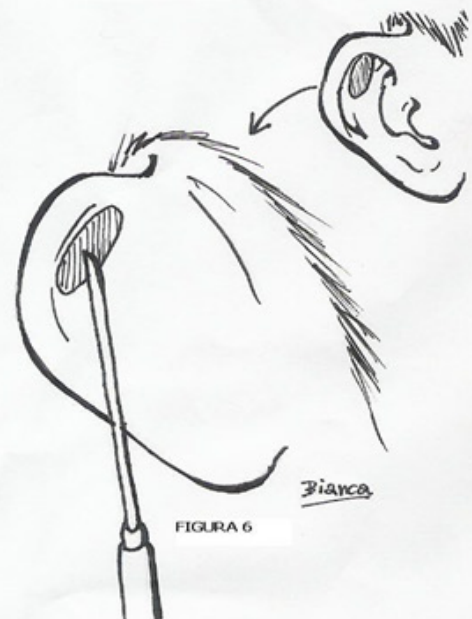
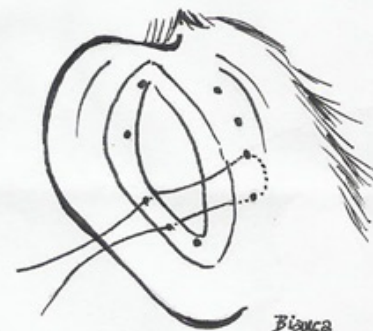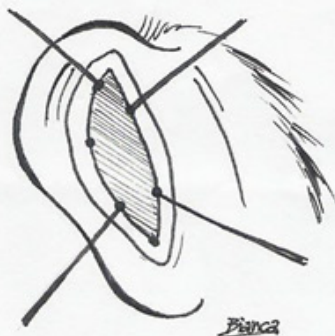
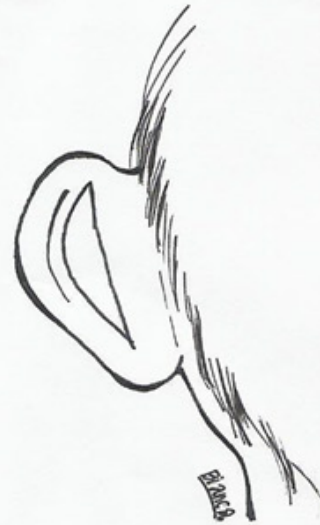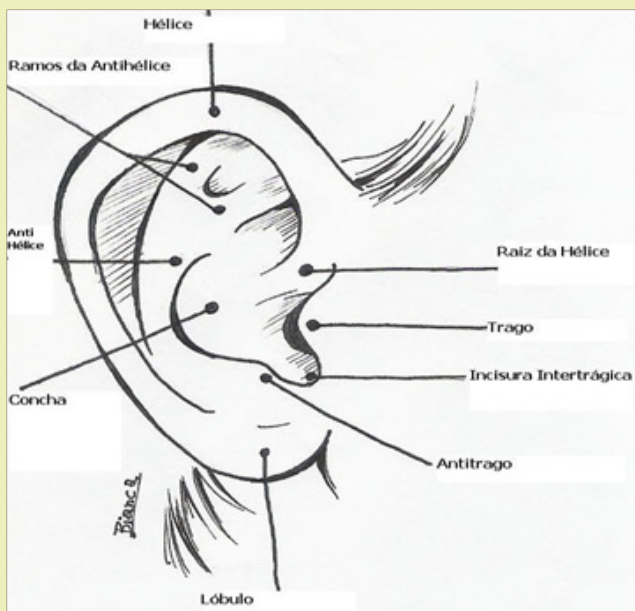
## Conflicts of Interest

Author declares that there is no conflict of interest.

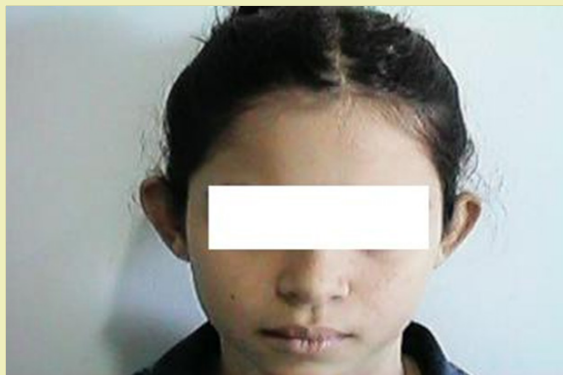## References

1. Welsh F. Otoplasty with excision of conchal floor. Transactions of the Seventh International Congress of Plastic. *Reconstructive Surgery Rio de Janeiro Brazil*. 1979.
2. Kaye BL. A simplified Method for correcting the Prominent ears. *Plast Reconstruct Surgery*. 1967;40(1):44-48.
3. Frank H Netter. 2<sup>nd</sup> ed; 2001.
4. Paoliello Victor. Types of skin suture in Plastic Surgery. *JBM*. 68(4):103-108.
5. Pitanguy Ivo. Body Contouring Surgery. Prominent ears. p. 306-314.





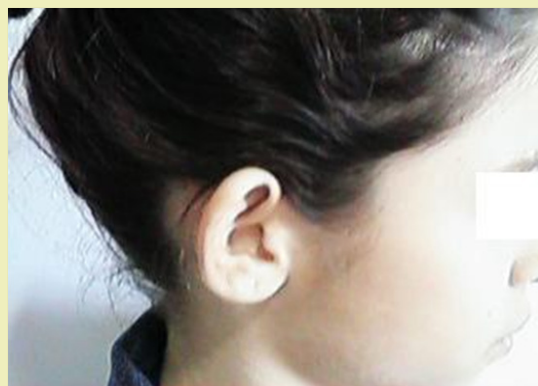




1- FRONT PRE OP



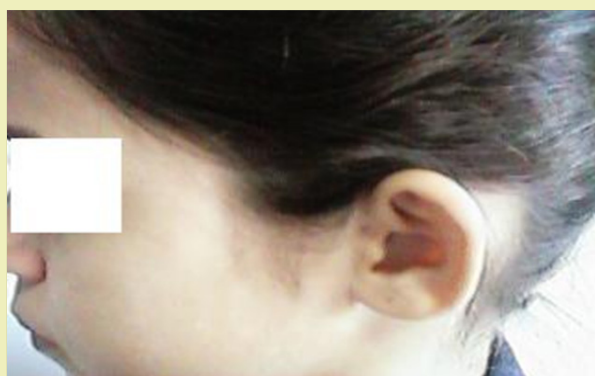
5 - POSTERIOR POST OP



2- PRE OP RIGHT LATERAL



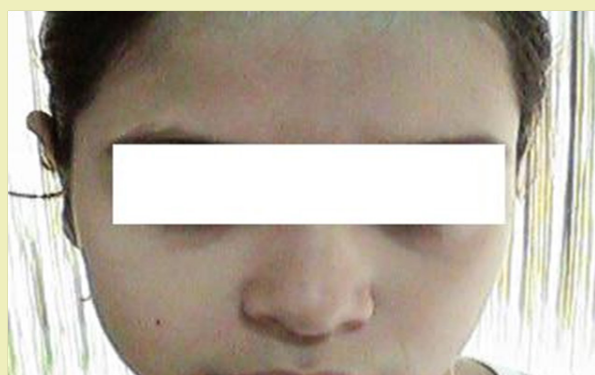6 PRE OP POSTERIOR




3 – PRE OP LEFT LATERAL



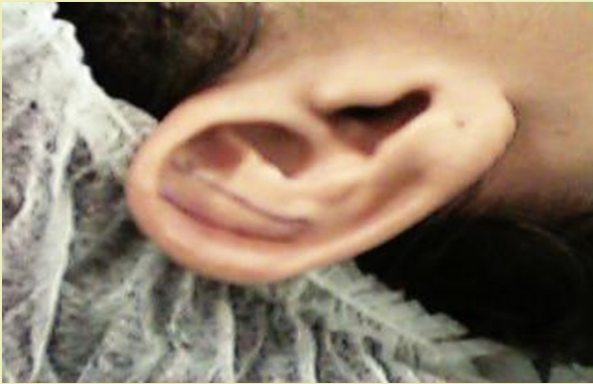7 – POST OP



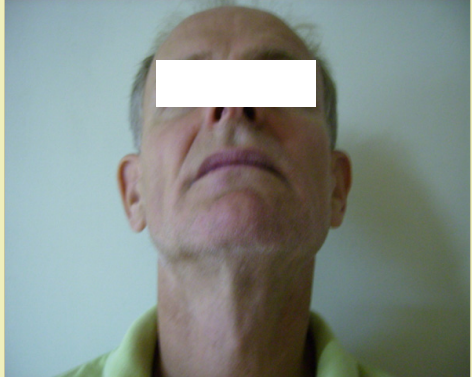4 – FRONT POST OP



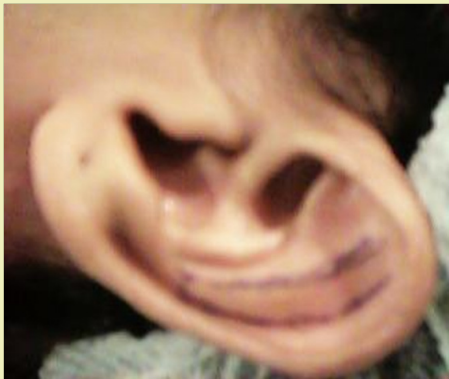8 – PRE OP



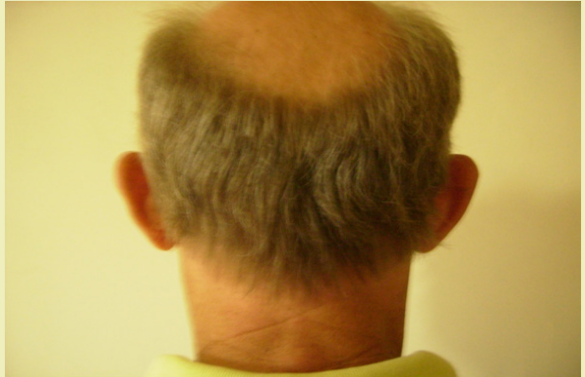9 – PRE OP



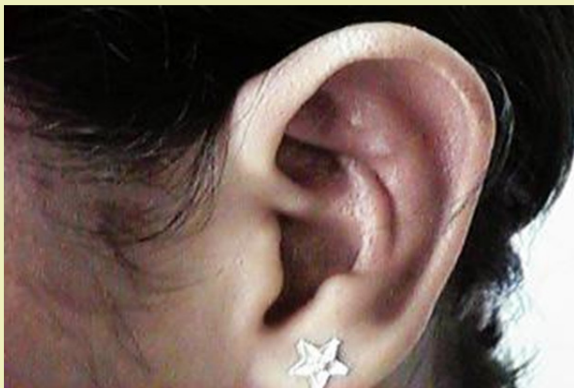13 – PRE OP



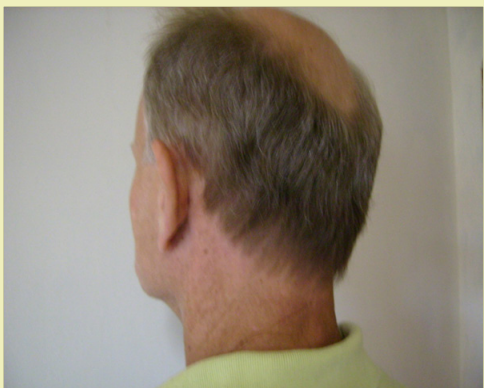10 – PRE OP



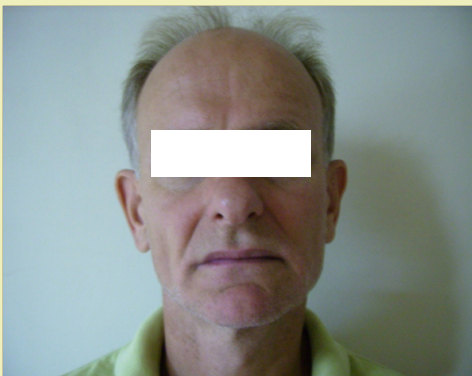14 – PRE OP



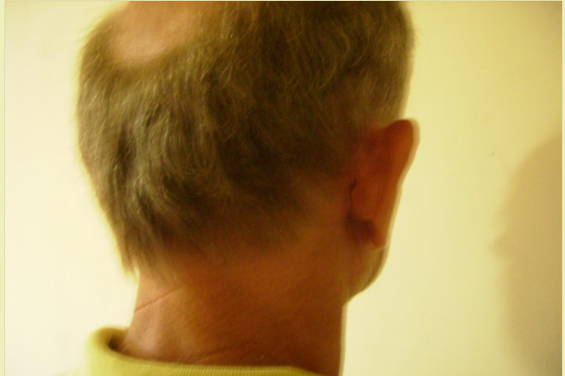11 - POST OP



15 – PRE OP

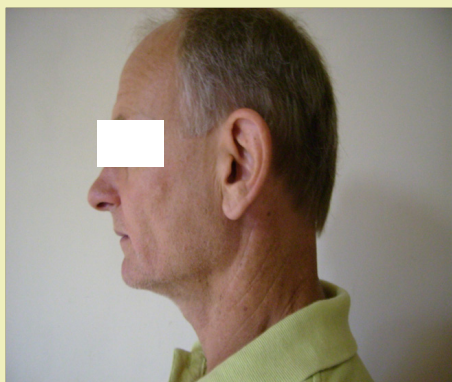

12 – PRE OP

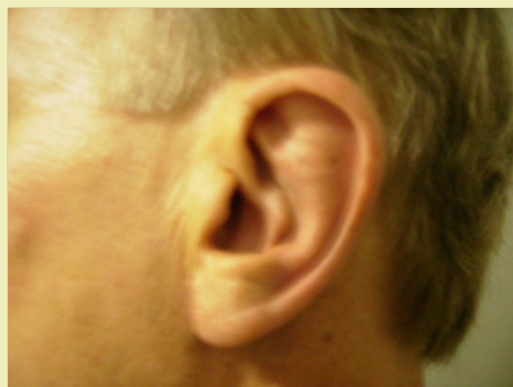

16 – PRE OP

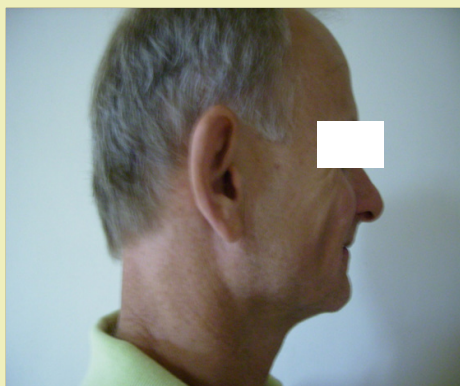



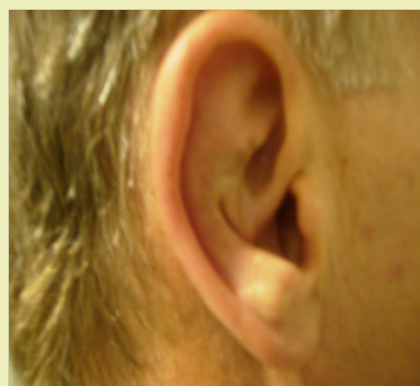17 – PRE OP



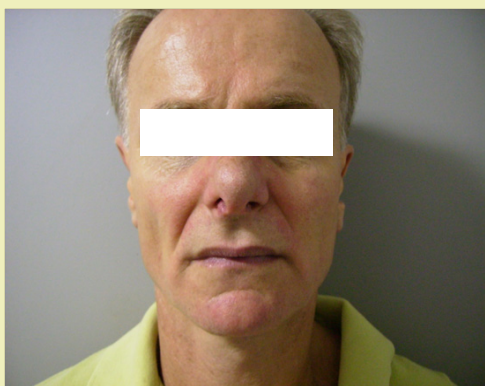
21- POST OP



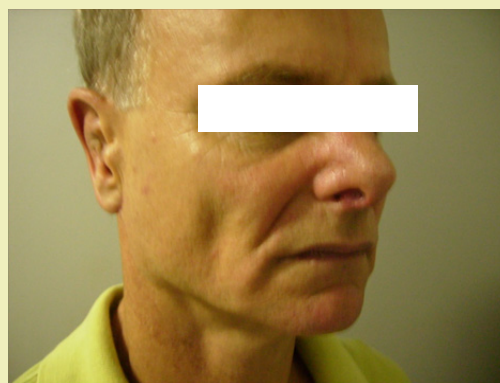18 – PRE OP



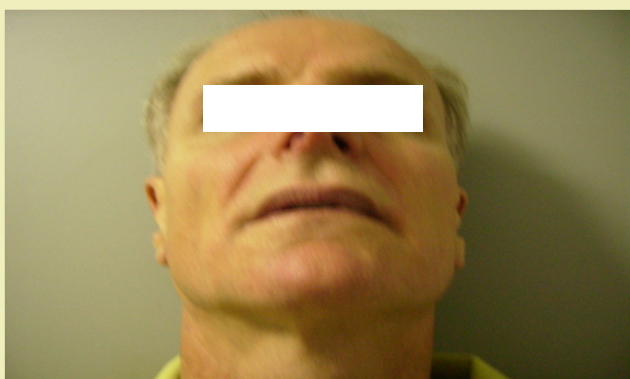
22 - POST OP



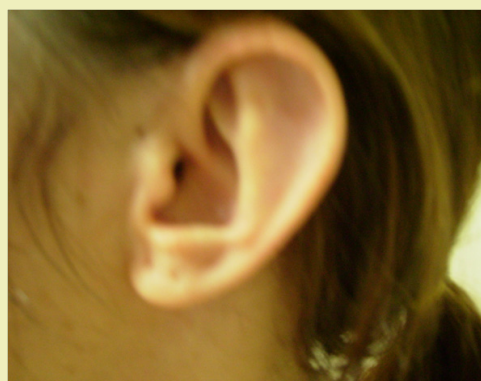19 - POST OP



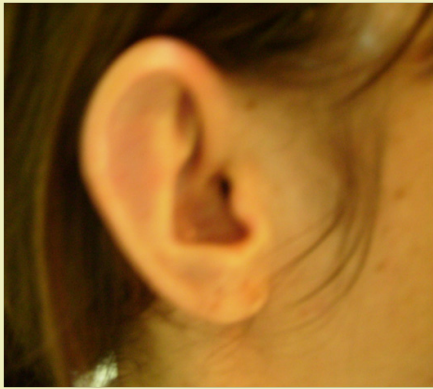23 - POST OP



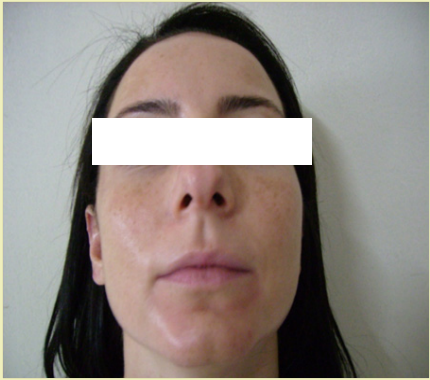20 - POST OP



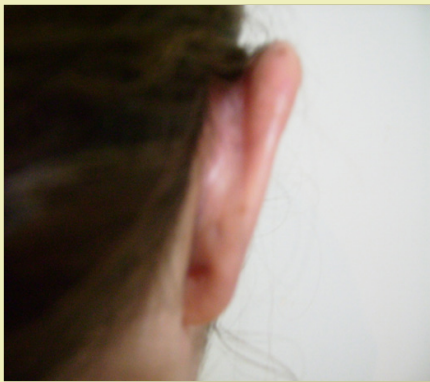24 - PRE OP



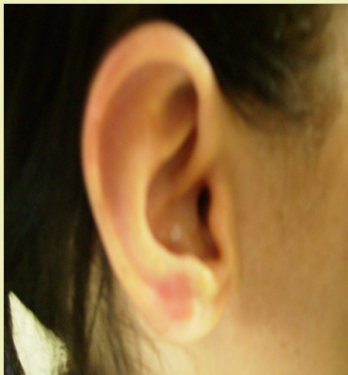25 - PRE OP



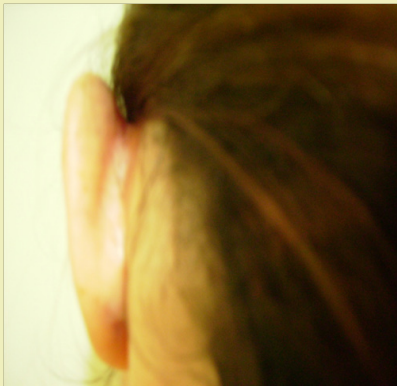29- POST OP



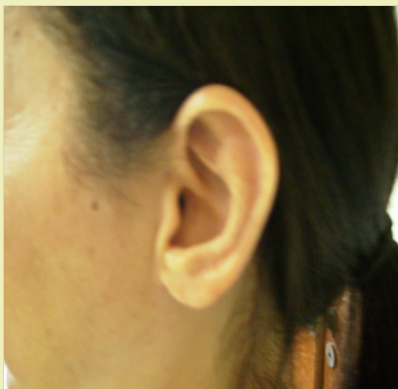26 - PRE OP



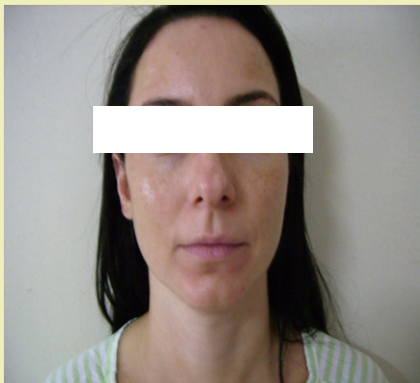30- POST OP



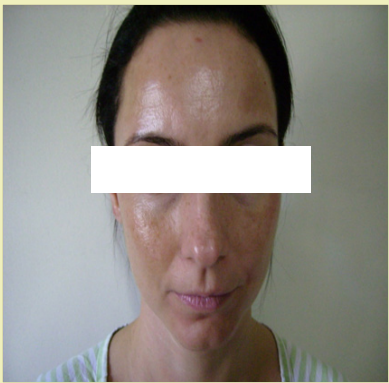27- PRE OP



31-POST OP



28 – POST OP



32- POST OP

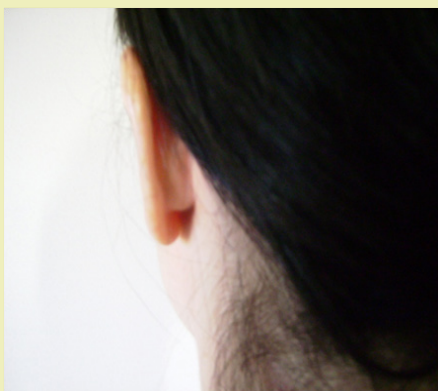



33 - POST OP



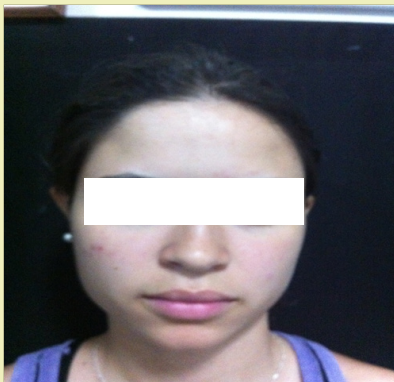37 - POST OP



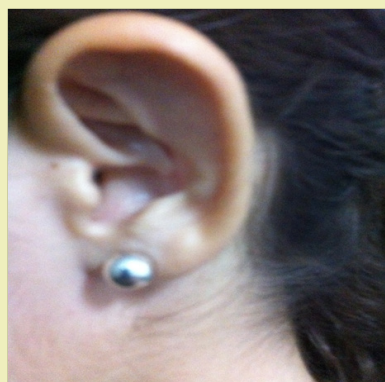
34 - POST OP



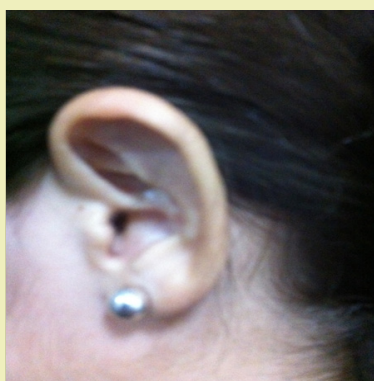38 - POST OP



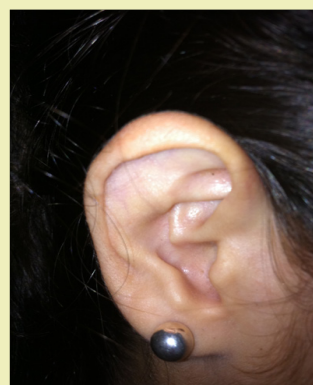35 - POST OP



39 - POST OP



36 - POST OP



40 - POST OP